

Nanotechnology Enhanced Spinal Fusion Devices for Bone Growth

Case Study- L4-5 Spondylolisthesis, L3-L5 TLIF with Pedicle Screw Fixation

Nanovis' Nano FortiFix and Nano FortiCore Spinal Instrumentation



Surgeon Profile
Todd Bonvallet, M.D.
Atlanta, GA

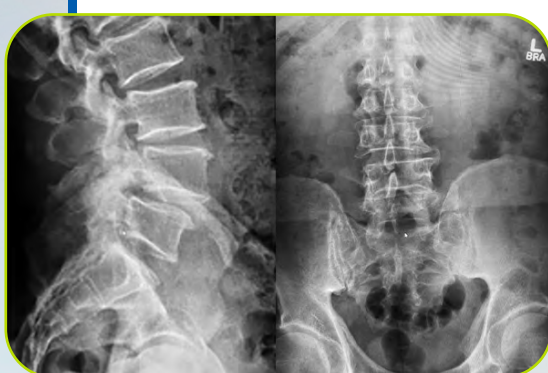Case Highlights

- ✔ 2-LEVEL TLIF
- ✔ MULTI-LEVEL CENTRAL AND FORAMINAL STENOSIS
- ✔ SPONDYLOLISTHESIS
- ✔ NANOTECHNOLOGY ENHANCED FUSION DEVICES FOR BONE GROWTH UTILIZED IN BOTH ANTERIOR AND POSTERIOR COLUMNS

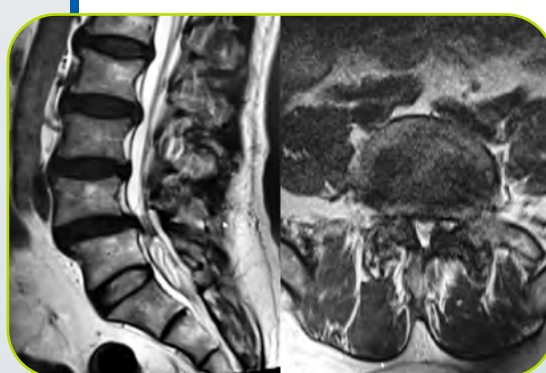
Clinical Presentation

A 60-year-old male presented in my clinic with a two-year history of low back pain, bilateral lower extremity pain with tingling and numbness, and neurogenic claudication. He failed conservative treatments for more than two years trying physical therapy, NSAIDS, epidural steroid injections, and pain management.

Pre-op Lateral and A/P X-Rays
Noted Disc Space Collapse at L4-5 and L5 Sagittal Deformity



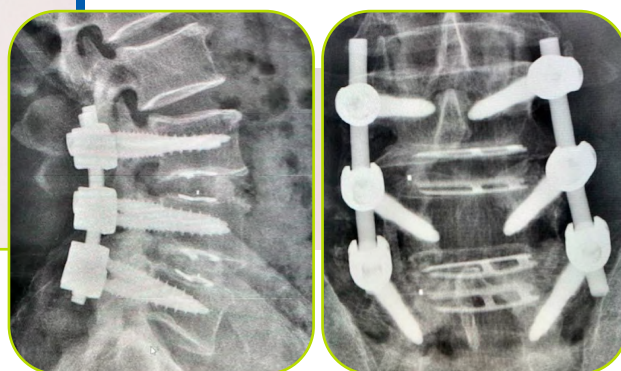
Pre-op Sagittal and Axial MRI
Noted Canal Stenosis from L4 Disc Herniation with Bilateral Nerve Root Impingement



Surgical Procedure

The patient consented for a 2-level TLIF L3/4, L4/5 with bilateral laminectomies and pedicle screw instrumentation. Autograft from bilateral laminectomy was morselized and placed in the graft chambers of the interbody fusion devices, along with a small dose of Infuse. Pedicle screws were placed bilaterally from L3-L5 without the use of robotics or navigation. Large TLIF devices were placed into the affected disc spaces and rotated into position.

Post-op Lateral and A/P X-Rays at 5 Months
Noted Sagittal Deformity Correction and Fusion Masses in Both Interbody Spaces at 5 Months
Bone Mineralization on Pedicle Screws Visible on A/P



Clinical Outcome

Early bone formation in the interbody fusion sites and posteriorly on the pedicle screws insured construct stability of the spinal instrumentation and contributed to a successful outcome for this patient. Additionally, the patient completed a standard physical therapy regimen prescribed for lumbar fusion patients. He is now one-year post-op and pain free for the first time in 3 years. Patient is back to normal activities and work schedule with only personal limitations.

Discussion





"As a spine surgeon, my primary goal is to achieve the best possible outcomes for my patients. One of the challenges we face in spinal surgery is the risk of pseudoarthrosis, or the failure of bone fusion to occur as intended. This can result in continued pain and instability, and may require additional surgery to correct.

To address this challenge, I have incorporated Nanovis' bone-growth Nanotechnology to support rapid bone growth on and through the fusion construct. While I am not a technology expert, I have been impressed with the results in the interbody space the last 3 years, and the last 18 months on pedicle screws. The nanotubes seem to promote rapid osseointegration, or the

formation of new bone tissue, around the implant sites, leading to faster and more complete fusion.

Every patient is unique and the risk of pseudoarthrosis is not always predictable preoperatively. However, I believe that using the latest technology available can help reduce the risk of complications and improve the overall success rate of spinal surgeries. I am excited about the potential benefits of Nanovis' technology for supporting rapid bone growth and fusion, and will continue to use it in my practice as part of my ongoing commitment to achieve the best possible outcomes for my patients."

Connect With Us

-  **Phone:** (877) 907-NANO
-  **Email:** info@nanovistechnology.com
-  **Address:** 5865 East State Road 14
Columbia City, IN 46725
United States
-  **LinkedIn**